

Published in final edited form as:

Neuroimage. 2007 October 1; 37(4): 1033–1058.

In praise of tedious anatomy

Joseph T. Devlin¹ and Russell A. Poldrack²

¹ Centre for Functional Magnetic Resonance of the Brain, University of Oxford

² Department of Psychology and Brain Research Institute, UCLA

Abstract

Functional neuroimaging is fundamentally a tool for mapping function to structure, and its success consequently requires neuroanatomical precision and accuracy. Here we review the various means by which functional activation can be localized to neuroanatomy and suggest that the gold standard should be localization to the individual's or group's own anatomy through the use of neuroanatomical knowledge and atlases of neuroanatomy. While automated means of localization may be useful, they cannot provide the necessary accuracy, given variability between individuals. We also suggest that the field of functional neuroimaging needs to converge on a common set of methods for reporting functional localization including a common "standard" space and criteria for what constitutes sufficient evidence to report activation in terms of Brodmann's areas.

Keywords

neuroanatomy; localization; cytoarchitecture; neuroimaging

"The lyf so short, the craft so long to lerne"

Geoffrey Chaucer, "The Parliament of Fowls"

One of the major challenges of functional neuroimaging is its interdisciplinary nature, with few researchers entering the field already expert in the full range of disciplines. Cognitive neuroscientists, for instance, often need to increase their knowledge of physics, signal processing, and statistics to avoid common imaging pitfalls. Researchers are aided by an increasingly standard set of tools and methods such as common imaging sequences and sophisticated analysis packages, but even these can not guarantee successful data acquisition or analyses without sufficient expertise to use them correctly. Neuroanatomy is another area critical to the success of imaging studies, but one which receives much less attention. After all, neuroimaging is fundamentally a tool for characterizing the structure and function of the central nervous system, but most neuroimagers do not have extensive anatomical training. The aim of this paper is to highlight the relation between functional imaging and the various levels of anatomical description available when reporting neuroimaging findings, in order to clarify the importance of accurate anatomical reporting. At present, anatomical localization practices are based largely on informal advice that varies considerably from lab to lab. We believe that it is essential for the neuroimaging community to move towards a consensus regarding localization practices and to this end, we suggest several possible ways that may help to reduce inaccuracy in the literature, improve transparency across studies, and facilitate the open and accurate exchange of information.

Levels of anatomical structure

One of the challenges of localization in functional neuroimaging is that anatomy can be understood at multiple levels and a complete understanding of any function requires relating information between levels. We begin by describing several different levels of anatomy that are specifically relevant to functional neuroimaging (Figure 1).

Macroanatomy

The basic three-dimensional structure of the brain is characterized by the gyral and sulcal landmarks of the cerebral cortex and the organization of gray matter in subcortical regions. It is this aspect of anatomy that is evident on the standard T1-weighted images that are acquired with most fMRI studies. Macroanatomy is generally consistent across normal individuals at a gross level but varies substantially between individuals in its details (Kennedy, Lange, Makris, Bates, Meyer, *et al.*, 1998; Thompson, Schwartz, Lin, Khan and Toga, 1996), even in identical twins (Thompson, Cannon, Narr, van Erp, Poutanen, *et al.*, 2001). For example, all humans have a transverse gyrus (known as Heschl's gyrus) in the superior temporal lobe that is associated with the primary auditory cortex, but the number and size of these transverse gyri varies considerably across individuals (Penhune, Zatorre, Macdonald and Evans, 1996; Rademacher, Morosan, Schormann, Schleicher, Werner, *et al.*, 2001). Similar variability is observed in every other cortical region (Ono, Kubik and Abernathy, 1990; Zilles, Armstrong, Schleicher and Kretschmann, 1988). The shape and relative locations of subcortical structures also differs between individuals, though perhaps less than that of the cerebral cortex. This variability in brain structure across individuals is critical, because it means that no two brains are identical at a macroscopic level and therefore no single brain is representative of a population. Consequently, any atlas based on a single "template" brain will necessarily provide limited accuracy in localising activations. In theory, it *may* be possible to determine a topographic transformation that could morph one brain into precise correspondence with another, although no current spatial normalisation tools even approach this ideal. Instead, normalisation procedures tend to correct only for gross anatomic variability and therefore claims regarding the localization of functional neuroimaging results are necessarily probabilistic.

Microanatomy

Although the brain's gray matter may seem homogenous from the standpoint of an MRI image, its microscopic structure is complex, and this fine structure is a critical determinant of the information processing that occurs in any particular brain region. The fine structure of the cortex can be characterized in a number of different manners, including the organization of cells across the layers of the cortex (cytoarchitecture), the myelination of axons in the cortex (myeloarchitecture), and the expression of neurotransmitter receptors (chemoarchitecture). The best known map of human microanatomy is the cytoarchitectural map of Brodmann (1909) and his system is probably the most commonly used scheme for labelling brain regions behind gyral/sulcal macroanatomy. The use of Brodmann's areas to label activation, however, relies upon the assumption that these areas are reliably associated with macrostructures, since microstructure is rarely available when imaging living humans (but see Bridge and Clare, 2006). Recent studies using a combination of neuroimaging and microscopy techniques call this assumption into question (Uylings, Rajkowska, Sanz-Arigita, Amunts and Zilles, 2005).

In a series of landmark studies, Zilles and colleagues have systematically investigated inter-subject variability in cortical cytoarchitecture and found that macroscopic borders are not good predictors of microscopic borders in many regions. For example, Amunts *et al.* (1999) investigated how well Brodmann's areas 44 and 45 correspond to the opercular and triangular portions of the inferior frontal gyrus (*i.e.* Broca's area), respectively. Areal borders such as the

one separating the two regions were not found at the bottom of the dividing sulcus (i.e. the fundus of the vertical ramus of the Sylvian fissure) but instead were located in either wall of the sulcus. Moreover, the precise location of the border was not predictable based on sulcal landmarks. In contrast, the crest of pars opercularis consistently corresponded to BA44 while the crest of pars triangularis corresponded to BA45. In other words, the tissue visible on the lateral surface of the brain could be reliably identified based on gyral patterns, although this only constitutes approximately one third of the total volume of the cortical sheet; the remaining two thirds is located within sulci where no systematic relation between macroscopic and microscopic borders exists. This degree of inter-subject variability is not only present in association cortices (Amunts, Schleicher, Burgel, Mohlberg, Uylings, *et al.*, 1999; Rajkowska and Goldman-Rakic, 1995) but is also found in primary and secondary visual (Amunts, Malikovic, Mohlberg, Schormann and Zilles, 2000), auditory (Morosan, Rademacher, Schleicher, Amunts, Schormann, *et al.*, 2001; Rademacher, Morosan, Schormann, Schleicher, Werner, *et al.*, 2001), somatosensory (Geyer, Schleicher and Zilles, 1999) and motor areas (Zilles, Schlaug, Matelli, Luppino, Schleicher, *et al.*, 1995). Consequently, relating functional activations to cytoarchitectonically defined regions such as Brodmann areas is problematic without probabilistic maps of underlying cytoarchitectonic variability (Uylings, Rajkowska, Sanz-Arigita, Amunts and Zilles, 2005) or concurrent high resolution imaging of individual participant's microstructure (Bridge, Clare, Jenkinson, Jezzard, Parker, *et al.*, 2005).

Connectivity

Brain regions are connected by white matter tracts which, like macroscopic and microscopic anatomy, can have substantial individual variability in terms of their position, extent, and course (Burgel, Amunts, Hoemke, Mohlberg, Gilsbach, *et al.*, 2006). Even so, the regional pattern of connectivity is largely preserved across individuals and these afferent and efferent pathways strongly influence the information processing properties of individual brain regions (Passingham, Stephan and Kotter, 2002). Consequently, it is often desirable to understand regional activations in terms of an underlying system of neural regions and their interactions (Friston, 2002a, b). To this end, advances in diffusion weighted tractography offer substantial potential for explicitly relating functional and connectional anatomy. For instance, regional connectivity patterns can be used to reliably identify both cortical (Anwander, Tittgemeyer, von Cramon, Friederici and Knosche, 2006; Johansen-Berg, Behrens, Robson, Drobniak, Rushworth, *et al.*, 2004) and subcortical regions (Behrens, Johansen-Berg, Woolrich, Smith, Wheeler-Kingshott, *et al.*, 2003; Devlin, Sillery, Hall, Hobden, Behrens, *et al.*, 2006; Lehericy, Ducros, Krainik, Francois, Van de Moortele, *et al.*, 2004) even when these areas lack clear macroanatomic borders. Consequently, by collecting connectivity information along with functional data, it is sometimes possible to directly relate structure and function in individuals.

Functional anatomy

The information present in most imaging studies concerns functional anatomy – that is, brain regions activated by performing one task relative to another. With a typical spatial resolution of several millimetres, these are naturally described in terms of macroanatomy. It is important to note, however, that activations rarely correspond to individual regions. Instead, they often spread across multiple areas, activating only specific parts of these regions. This is hardly surprising given that macroanatomic regions tend to be fairly large (on the order of centimetres) and both functionally and structurally heterogeneous. Thus, it can be helpful to precisely identify functionally-defined regions such as early visual areas V1–V4 (Sereno, Dale, Reppas, Kwong, Belliveau, *et al.*, 1995) and use this information to interpret activation in the main experiment (e.g. Vanduffel, Fize, Peuskens, Denys, Sunaert, *et al.*, 2002). Although there is a debate concerning the optimal implementation of “functional localiser scans” (Friston, Rotshtein, Geng, Sterzer and Henson, 2006; Saxe, Brett and Kanwisher, 2006), their value in interpreting activation patterns is unquestioned.

How do I know where my activation is?

After completing a functional imaging analysis, the results are often displayed by the analysis software in a table showing standard space coordinates and corresponding statistics for significant clusters of activation but without any mention of anatomy. The researcher's first goal is often to determine what anatomical structures in the brain are represented by these coordinates. Although coordinates are useful to report (e.g. for the purposes of meta-analyses), they are most beneficial when accompanied by a description of the underlying anatomy. For instance, typographic errors in coordinates can result in considerable confusion (Nielsen and Hansen, 2002) whereas a description of the anatomy is far less ambiguous. More importantly, summary coordinates describe single peaks whereas clusters of activation are usually more extensive and may encompass more than one anatomical structure. The problem that arises, however, is that there is no deterministic algorithm for assigning anatomical labels to stereotactic coordinates. So, how should the researcher proceed? We believe an essential first step is to visualize the activation overlaid directly on the anatomy.

Visualizing individual data

When viewing an individual participant's activation, it is clear that the most accurate anatomical description relies on overlaying the statistical maps onto that individual's T1-weighted scan. Obviously, distortion and signal dropout affect the quality of the registration limiting the spatial precision of the overlay, and the problem is compounded for small, atrophied or lesioned brains (Brett, Leff, Rorden and Ashburner, 2001). Even so, most analysis software packages provide tools for manually checking the registration and ensuring an adequate correspondence, usually by visual comparison. It then becomes most useful to use a tool that provides simultaneous viewing in all three canonical orientations at once (see Figure 2). Because no two brains are identical, it is inappropriate to display individual activation on a "standard" brain such as the Colin27 high-resolution image as this can lead to inaccurate reporting of the anatomy. Consequently, tools based on this template such as Automated Anatomical Labeling (AAL: Tzourio-Mazoyer, Landeau, Papathanassiou, Crivello, Etard, *et al.*, 2002) should be used with caution. Similarly, atlases based on a single "representative" brain which include "standard space" coordinate systems such as Talairach and Tournoux (1988) atlas (hereafter T&T) or Schmahmann *et al.*'s (2000) cerebellar atlas also must be used judiciously as a coordinate in the atlas may not correspond to the same anatomical structure in each participant. The strength of these tools is their ability to narrow down the search to a small set of regions such that the correct anatomical label can then be identified based on the macroanatomic landmarks in the individual's structural image, often with the aid of one or more brain atlases.

There are many brain atlases available to assist in anatomical localisation as well as some useful web sites (see Appendix). One that we find particularly useful is the Duvernoy (1991) atlas which presents MRI images in all three canonical planes as well as photographs of matching brain slices. The lack of a coordinate system in the atlas forces one to localize not by coordinates but in terms of relevant macroanatomical landmarks. Although it seems simple, it is often helpful to start with the central sulcus and Sylvian fissure as these are the two clearest landmarks due to their size and relatively small variability across people (Fischl, Salat, Busa, Albert, Dieterich, *et al.*, 2002; Van Essen, 2005). From there, one can usually locate the sulci nearest the activation and using the atlas, determine the name of the cortical territory. In addition to Duvernoy (which is currently being re-issued by the publisher), there are several other atlases that can also be useful (e.g. Mai, Assheuer and Paxinos, 2004; Woolsey, Hanaway and Gado, 2003) and there are specialty atlases for specific brain regions such as cerebellum (Schmahmann, Doyon, Toga, Petrides and Evans, 2000), hippocampus (Duvernoy, 2005), subcortical structures (Lucerna, Salpietro, Alafaci and Tomasello, 2004), and white matter

tracts (Mori, Wakana and Van Zijl, 2004). The highly skilled neuroanatomist may be able to accurately label most structures without an atlas, but for the rest of us one or more good atlases are essential. Moreover, the process of examining the anatomy closely leads to a better appreciation of anatomical variability, increases one's ability to correctly identify these structures in the future, and builds up a 3D internal mental model of neuroanatomy in the researcher which is invaluable for neuroimaging.

There are a number of reasons not to include the T&T atlas in the foregoing list. In short, we believe that localization based on the T&T atlas is an alluringly easy but bad option (cf. Brett, Johnsrude and Owen, 2002; Uylings, Rajkowska, Sanz-Arigita, Amunts and Zilles, 2005). It is easy because the atlas has an overlaid coordinate system which makes it trivial to identify an activated location. It is nonetheless a bad option because this provides a false sense of precision and accuracy, for a number of reasons:

1. The atlas is based on the single brain of a 60-year old woman, and therefore not representative of either the population as a whole nor any individuals.
2. Almost all major analysis packages use the templates based on the MNI305 atlas as their target for spatial normalization, which are population based (and therefore representative) templates. An extra step is needed to convert coordinates into T&T space and this introduces additional registration error. Worse still, there is no consensus regarding how to perform this transformation (Brett, Johnsrude and Owen, 2002; Carmack, Spence, Gunst, Schucany, Woodward, *et al.*, 2004) and therefore the chosen method biases the results, introducing additional variation and therefore reducing accuracy.
3. The atlas is based on a single left hemisphere that was reflected to model the other hemisphere. However, there are well known hemispheric asymmetries in normal individuals (e.g., location of Heschl's gyrus, length of precentral gyrus), such that assuming symmetry across hemispheres will result in additional inaccuracy.
4. The T&T atlas is labelled with Brodmann's areas, but the precision of these labels is highly misleading. The labels were transferred manually from the Brodmann's map by T&T, and even according to T&T the mapping is uncertain (see Brett, Johnsrude and Owen, 2002; Uylings, Rajkowska, Sanz-Arigita, Amunts and Zilles, 2005).

For all of these reasons, the T&T atlas is not a good choice. Likewise, we believe that automated coordinate-based labelling methods based on the T&T atlas (such as the Talairach Daemon, Lancaster, Woldorff, Parsons, Liotti, Freitas, *et al.*, 2000) are problematic. We believe that it is much better to take the nominally more difficult, but far more accurate route of using an anatomical atlas rather than one based on coordinates.

Another option available to researchers is to use a software package capable of automatically labeling individual T1-weighted images using standard anatomical parcellation schemes (Cachia, Mangin, Riviere, Papadopoulos-Orfanos, Kherif, *et al.*, 2003; Desikan, Segonne, Fischl, Quinn, Dickerson, *et al.*, 2006; Fischl, Salat, Busa, Albert, Dieterich, *et al.*, 2002; Fischl, van der Kouwe, Destrieux, Halgren, Segonne, *et al.*, 2004; Lohmann and von Cramon, 2000; Mega, Dinov, Mazziotta, Manese, Thompson, *et al.*, 2005). In brief, these rely on automated methods for identifying sulci and matching them to labelled models in order to name anatomical territories. Although these can be very helpful when identifying anatomical regions, the labellings are not 100% accurate across individuals and consequently it is important to manually verify the labelling, again with reference to an atlas.

Visualizing group data

The same set of issues apply when identifying activations in group studies, with the added complication that the activations are derived from multiple anatomies. Thus, overlaying the activation on a single template image such as the Colin27 brain implies an anatomical precision that is not warranted. Instead, the activation should be visualized on a mean structural image from the group coregistered to the functional data. Although this appears less precise due to inter-subject morphological variability blurring macroanatomical landmarks, it accurately reflects the imprecision in the functional data due to underlying anatomical variability. In many cases, sufficient detail remains to reliably identify anatomical territories, but in some cases, it may be necessary to examine the location of activation in each individual and report the anatomy probabilistically (e.g. “activation was present in the posterior portion of pars triangularis in 81% of participants and in anterior pars opercularis in 19%”).

As with visualization of individual data, the use of single-subject atlases can be misleading regarding anatomical localization in group data. Image-based probabilistic atlases such as the LONI Probabilistic Atlas (Shattuck, Hojatkashani, Mirza, Adisetiyo, Salamon, *et al.*, 2006), the Population-Averaged Landmark- and Surface (PALS) based atlas (Van Essen, 2005) and Hammers *et al.*'s (2003) atlas may be useful as they provide an explicit measure of the individual variability in macroanatomical structure at any coordinate. Thus, one can report the likelihood that activation occurs in a particular region. Alternatively, these atlases can be used to create regions of interest that can be directly interrogated for activation.

Using surface-based methods (Fischl, Sereno and Dale, 1999; Van Essen, 2005), it is possible to reconstruct the cortical surface of individual subjects, such that one can view activation overlaid simultaneously on the cortical surface (often inflated for better viewing of sulci) and the anatomical volume (see Figure 2). This can be a very useful way to visualize activation, as it provides a three-dimensional perspective that can be difficult to gain from anatomical slices alone. In addition, data can be registered by alignment of cortical surface features and then analyzed in surface space, which can sometimes provide better alignment across subjects than volume-based alignment (Desai, Liebenthal, Possing, Waldron and Binder, 2005). However, these methods often require substantial processing time and manual intervention in order to accurately reconstruct the cortical surface. Recently, a method has been developed that allows projection of individual or group functional activation onto a population-based surface atlas (Van Essen, 2005). This method, known as multifiducial mapping, maps the activation data to the cortical surfaces of a group of subjects and then averages those mappings, thus avoiding the bias that would result from mapping group data onto a single subject's surface. Although individual reconstruction will remain the gold standard for mapping activation data to the cortical surface, the multi-fiducial mapping technique (implemented in the CARET software package) provides a useful means for viewing projections of group activation data on a population-averaged cortical surface.

In summary, accurate identification of the underlying anatomy is a difficult task that can be both time consuming and tedious. There are many automated tools that can be useful in helping to determine the anatomical localization of functional activations, though in the end they are still heuristic. The atlas-based methods based on populations are potentially more useful than those based on single brains, since they highlight the uncertainty regarding localization of group fMRI data. We are also excited about the development of increasingly reliable and accurate automated labelling techniques, since these should in theory provide a great deal of accuracy for anatomical localization at the individual level. In our opinion, the primary value of these tools for functional neuroimaging is their ability to assist researchers in the process of learning neuroanatomy. Indeed, we believe that like standard pulse sequences and analysis software, they are an essential component of the neuroimaging toolkit, but they in no way eliminate the need to learn neuroanatomy. The manual process of providing detailed and accurate anatomical

descriptions of activation helps one to develop a mental model of neuroanatomy. And like any difficult skill, learning neuroanatomy can be a fairly daunting task but it occurs implicitly over time simply by going through this process with the activations in one's own studies.

Reporting activations

Having localized the results to anatomical structures, the researcher must then decide how to report this localization for publication. Given the spatial resolution of fMRI and PET, it makes sense to describe activation in terms of macroanatomy since T1-weighted images are routinely acquired, providing an important (but underused) link with macroanatomy. In some cases, additional data may be collected to assist in functional or structural localization, such as functional localisers (e.g., scans to identify retinotopically mapped visual cortical regions: Engel, Rumelhart, Wandell, Lee, Glover, *et al.*, 1994), anatomical localizers based on structural features (Barbier, Marrett, Danek, Vortmeyer, van Gelderen, *et al.*, 2002) or anatomical localisers based on connectivity (Johansen-Berg, Behrens, Robson, Drobnjak, Rushworth, *et al.*, 2004). Each of these can be particularly powerful for relating activation and macroanatomy to microstructure and function, and should be used if possible. When these methods are not an option, the spatial resolution of imaging dictates the need to solely report macroanatomy.

Nearly all neuroimaging papers report tables with stereotactic coordinates and associated anatomical labels. At the moment, these coordinates are reported in either the space defined by the Talairach atlas (which we'll call T&T space) or that defined by the MNI template (which we'll call MNI space). There is currently some confusion regarding what is meant by a "standard space" in neuroimaging publications (cf. Brett *et al.*, 2002), which is exacerbated by the tendency to use the term "Talairach space" as a generic label for any stereotactic space. In the early days of neuroimaging, T&T space was the standard, but it has largely been supplanted by MNI space. Almost all major analysis packages use templates based on the MNI305 space as a default for normalization, which makes it the natural space for reporting results. This is for good reason, as the T&T space is based a single brain and therefore is not representative, whereas the MNI atlas is population-based and therefore much more representative. For these reasons, MNI space was chosen by the International Consortium for Brain Mapping (ICBM) as the "standard" for neuroimaging experiments. However, the presence of multiple standards in the literature continues to lead to confusion, and the lack of a standard "bridge" that provides a 1:1 mapping between spaces means that noise will be introduced by any traversal across spaces. It makes little sense to normalize to MNI space and then convert the results to the T&T space for reporting purposes, particularly given the aforementioned problems with the T&T system. By adopting a single standard, the community would improve both accuracy and transparency when reporting activations.

With regard to reporting of results, it is also critical that the details of the spatial normalization procedure are described in any neuroimaging publication. This should include a description of the software that is used for normalization and the parameters used with that software, such as whether the normalization was linear or nonlinear and how many parameters were used in the transformation. In addition, the specific target used for normalization should be specified (e.g., "the data were spatially normalized to the MNI avg152 T1-weighted template using a 12-parameter affine transformation with FLIRT"). These details are particularly important given that there appear to be differences in the resulting stereotactic spaces between different versions of the MNI template and different normalization software (D. Dierker & D. Van Essen, personal communication).

Reporting Brodmann's areas

In many neuroimaging papers, activations are reported in terms of Brodmann's areas in addition to macroanatomical structure, in part because it allows for homologies to other species (e.g.,

Petrides, 2005) which can enable inferences about anatomical connectivity (Passingham, Stephan and Kotter, 2002). One commonly used approach is to determine BA labels based on the T&T atlas, either manually or using automated means such as the Talairach Daemon. However, as discussed above, the BA labels in the T&T atlas are really just “guesstimates” about the actual location of Brodmann’s areas. Another approach is to infer BA labels from macroanatomy using Brodmann’s original map as a guide; for example, activation in the triangular portion of the inferior frontal gyrus is often assigned to BA45 based on their correspondence in Brodmann’s original atlas. However, it is now clear that cytoarchitecture does not map cleanly onto macroanatomy; in particular, borders of Brodmann’s areas do not match sulcal boundaries, and there is substantial variability in the relation between Brodmann’s areas and macroanatomy (Amunts, Schleicher, Burgel, Mohlberg, Uylings, *et al.*, 1999). Consequently, informal estimates of Brodmann areas are unwarranted and should be avoided (Uylings, Rajkowska, Sanz-Arigita, Amunts and Zilles, 2005).

A far more accurate method is to use the probabilistic BA maps generated by Zilles and colleagues. These maps (available in standard image formats normalized to the MNI space) are based on post-mortem histology from multiple brains, yielding a probabilistic estimate of locations that explicitly includes variability. The SPM Anatomy Toolbox (Eickhoff, Stephan, Mohlberg, Grefkes, Fink, *et al.*, 2005), for example, allows the integration of these maps with functional imaging analysis. The limitation of this approach is that, due to the painstakingly difficult nature of this work, these maps only exist for some regions so it may not be possible to identify each BA region for a set of activations in a study. In this case, we would argue that it is best to forego estimates about putative BA regions, rather than providing estimates that are guaranteed to be inaccurate. Any other method of BA labelling is at best a guess regarding the true cytoarchitecture of a cortical region, which simply introduces noise into the literature.

The importance of accurate anatomical reporting becomes evident when comparing results across studies. How meaningful is it, for instance, to note that faces, objects, and written words all activate BA37 if the activations encompass at least three distinct subfields in the mid-fusiform gyrus, lateral occipital complex, and posterior occipito-temporal sulcus, respectively? The use of coarse (or, in the case of Brodmann’s areas, potentially inaccurate) labels significantly complicates the problem of “reverse inference,” or the ability to infer cognitive processes from the location of an activation (Poldrack, 2006). On the other hand, despite anatomical and registration-induced variability, there is often considerable overlap between similar studies, suggesting the presence of an important functional unit. Regardless of whether the activation corresponds to a clearly defined functional region, it can always be described precisely with reference to sulcal and gyral landmarks, making it readily identifiable in subsequent studies. This extra anatomical precision facilitates comparisons across studies, improves the sensitivity of meta-analyses, and reduces unnecessary “noise” when inferring cognitive processes from activations.

Conclusions

Accurate anatomical localization is central to the success of functional imaging. Consequently, the anatomical locations reported in imaging studies need to be as informative and accurate as possible, and this relies on localizing activations using the best information that is available. Sometimes this may include functionally-defined regions or structurally defined regions based on connectivity, high resolution structural imaging, or on cytoarchitecture. In most cases, however, activations should be described in terms of the underlying macroanatomy and the description based on the structural images collected as part of the study. This should improve comparability between studies and will certainly reduce a major source of variability when making “reverse inferences” (Poldrack, 2006).

To this end, we encourage the use of anatomical atlases in localization of functional activation. We believe that there is absolutely no alternative to a detailed knowledge of neuroanatomy for neuroimaging researchers, and that the only way to obtain this knowledge is by spending many hours with an atlas. Fortunately, this knowledge builds up gradually over time by simply making the effort to identify individual anatomical regions in one's own studies. This practice helps individual researchers develop 3D mental models of neuroanatomy and leads to a better appreciation of anatomy at multiple levels. There are a number of tools to help with this, but in the end it is the responsibility of the individual investigator to report the anatomy accurately, and the responsibility of the community to raise our standards of reporting to ensure that this happens.

Finally, the research community as a whole can also improve the standards for anatomical reporting by adopting a few simple measures. First, the community should agree upon a single standard for "standard space" and enforce this choice. This will increase consistency of reporting between studies and therefore the clarity and exchangeability of information. We have argued that it should be the MNI space and that there is no good reason to keep using the T&T system, since it is both unrepresentative and inaccurate. Second, neuroimaging researchers should stop using the term "Talairach space" to refer the MNI coordinate space, as this simply adds to the confusion. Third, journals and professional societies should adopt a clear policy on reporting results, including guidelines on reporting the details of spatial normalization methods and targets, the description of stereotactic spaces, and the kind of information that can be presented. For instance, it would be particularly useful to have a clear policy regarding whether Brodmann's areas can be inferred (e.g. from the T&T atlas) or require cytoarchitectonic information such as the probabilistic maps of Zilles and colleagues (Eickhoff, Stephan, Mohlberg, Grefkes, Fink, *et al.*, 2005). Obviously, "best practice" needs to be determined by the community as a whole. Towards this end, we hope that our commentary stimulates discussion of these important issues and may help to develop a consensus on anatomical localization and reporting within the neuroimaging community.

Acknowledgements

This work was supported by the Wellcome Trust (J. Devlin), NSF DMI-0433693 (R. Poldrack, PI), and NIH P20 RR020750 (R. Bilder, PI). Thanks to Adam Aron, Robert Bilder, Donna Dierker, David Van Essen and Richard Wise for helpful comments.

References

- Amunts K, Malikovic A, Mohlberg H, Schormann T, Zilles K. Brodmann's areas 17 and 18 brought into stereotaxic space-where and how variable? *Neuroimage* 2000;11:66–84. [PubMed: 10686118]
- Amunts K, Schleicher A, Burgel U, Mohlberg H, Uylings HB, et al. Broca's region revisited: Cytoarchitecture and intersubject variability. *J Comp Neurol* 1999;412:319–341. [PubMed: 10441759]
- Anwander A, Tittgemeyer M, von Cramon DY, Friederici AD, Knosche TR. Connectivity-based parcellation of Broca's area. *Cereb Cortex*. 2006
- Barbier EL, Marrett S, Danek A, Vortmeyer A, van Gelderen P, et al. Imaging cortical anatomy by high-resolution mr at 3.0t: Detection of the stripe of gennari in visual area 17. *Magn Reson Med* 2002;48:735–738. [PubMed: 12353293]
- Behrens TE, Johansen-Berg H, Woolrich MW, Smith SM, Wheeler-Kingshott CA, et al. Non-invasive mapping of connections between human thalamus and cortex using diffusion imaging. *Nat Neurosci* 2003;6:750–757. [PubMed: 12808459]
- Brett M, Johnsrude IS, Owen AM. The problem of functional localization in the human brain. *Nat Rev Neurosci* 2002;3:243–249. [PubMed: 11994756]
- Brett M, Leff AP, Rorden C, Ashburner J. Spatial normalization of brain images with focal lesions using cost function masking. *Neuroimage* 2001;14:486–500. [PubMed: 11467921]

- Bridge H, Clare S. High-resolution mri: In vivo histology? *Philos Trans R Soc Lond B Biol Sci* 2006;361:137–146. [PubMed: 16553313]
- Bridge H, Clare S, Jenkinson M, Jezzard P, Parker AJ, et al. Independent anatomical and functional measures of the v1/v2 boundary in human visual cortex. *J Vis* 2005;5:93–102. [PubMed: 15831070]
- Brodmann, K. Localisation in the cerebral cortex. Verlag von Johann Ambrosias Barth; Leipzig: 1909.
- Burgel U, Amunts K, Hoemke L, Mohlberg H, Gilsbach JM, et al. White matter fiber tracts of the human brain: Three-dimensional mapping at microscopic resolution, topography and intersubject variability. *Neuroimage* 2006;29:1092–1105. [PubMed: 16236527]
- Cachia A, Mangin JF, Riviere D, Papadopoulos-Orfanos D, Kherif F, et al. A generic framework for the parcellation of the cortical surface into gyri using geodesic voronoi diagrams. *Med Image Anal* 2003;7:403–416. [PubMed: 14561546]
- Carmack PS, Spence J, Gunst RF, Schucany WR, Woodward WA, et al. Improved agreement between talairach and mni coordinate spaces in deep brain regions. *Neuroimage* 2004;22:367–371. [PubMed: 15110028]
- Clare S, Bridge H. Methodological issues relating to in vivo cortical myelography using mri. *Hum Brain Mapp* 2005;26:240–250. [PubMed: 15954140]
- Desai R, Liebenthal E, Possing ET, Waldron E, Binder JR. Volumetric vs. Surface-based alignment for localization of auditory cortex activation. *Neuroimage* 2005;26:1019–1029. [PubMed: 15893476]
- Desikan RS, Segonne F, Fischl B, Quinn BT, Dickerson BC, et al. An automated labeling system for subdividing the human cerebral cortex on mri scans into gyral based regions of interest. *Neuroimage* 2006;31:968–980. [PubMed: 16530430]
- Devlin JT, Sillery EL, Hall DA, Hobden P, Behrens TE, et al. Reliable identification of the auditory thalamus using multi-modal structural analyses. *Neuroimage*. 2006
- Duvernoy, H. The human brain: Surface, three dimensional sectional anatomy and mri. Springer-Verlag; NY: 1991.
- Duvernoy, HM. The human hippocampus : Functional anatomy, vascularization, and serial sections with mri. 3rd.. Springer; Berlin: 2005.
- Eickhoff SB, Stephan KE, Mohlberg H, Grefkes C, Fink GR, et al. A new spm toolbox for combining probabilistic cytoarchitectonic maps and functional imaging data. *Neuroimage* 2005;25:1325–1335. [PubMed: 15850749]
- Engel SA, Rumelhart DE, Wandell BA, Lee AT, Glover GH, et al. Fmri of human visual cortex. *Nature* 1994;369:525. [PubMed: 8031403]
- Fischl B, Salat DH, Busa E, Albert M, Dieterich M, et al. Whole brain segmentation: Automated labeling of neuroanatomical structures in the human brain. *Neuron* 2002;33:341–355. [PubMed: 11832223]
- Fischl B, Sereno MI, Dale AM. Cortical surface-based analysis. Ii: Inflation, flattening, and a surface-based coordinate system. *Neuroimage* 1999;9:195–207. [PubMed: 9931269]
- Fischl B, van der Kouwe A, Destrieux C, Halgren E, Segonne F, et al. Automatically parcellating the human cerebral cortex. *Cereb Cortex* 2004;14:11–22. [PubMed: 14654453]
- Friston K. Beyond phrenology: What can neuroimaging tell us about distributed circuitry? *Annu Rev Neurosci* 2002a;25:221–250. [PubMed: 12052909]
- Friston K. Functional integration and inference in the brain. *Prog Neurobiol* 2002b;68:113–143. [PubMed: 12450490]
- Friston KJ, Rotshtein P, Geng JJ, Sterzer P, Henson RN. A critique of functional localisers. *Neuroimage* 2006;30:1077–1087. [PubMed: 16635579]
- Geyer S, Schleicher A, Zilles K. Areas 3a, 3b, and 1 of human primary somatosensory cortex. *Neuroimage* 1999;10:63–83. [PubMed: 10385582]
- Hammers A, Allom R, Koepp MJ, Free SL, Myers R, et al. Three-dimensional maximum probability atlas of the human brain, with particular reference to the temporal lobe. *Hum Brain Mapp* 2003;19:224–247. [PubMed: 12874777]
- Johansen-Berg H, Behrens TE, Robson MD, Drobnjak I, Rushworth MF, et al. Changes in connectivity profiles define functionally distinct regions in human medial frontal cortex. *Proc Natl Acad Sci U S A* 2004;101:13335–13340. [PubMed: 15340158]

- Kennedy DN, Lange N, Makris N, Bates J, Meyer J, et al. Gyri of the human neocortex: An mri-based analysis of volume and variance. *Cereb Cortex* 1998;8:372–384. [PubMed: 9651132]
- Lancaster JL, Woldorff MG, Parsons LM, Liotti M, Freitas CS, et al. Automated talairach atlas labels for functional brain mapping. *Hum Brain Mapp* 2000;10:120–131. [PubMed: 10912591]
- Lehericy S, Ducros M, Krainik A, Francois C, Van de Moortele PF, et al. 3-d diffusion tensor axonal tracking shows distinct sma and pre-sma projections to the human striatum. *Cereb Cortex* 2004;14:1302–1309. [PubMed: 15166103]
- Lohmann G, von Cramon DY. Automatic labelling of the human cortical surface using sulcal basins. *Med Image Anal* 2000;4:179–188. [PubMed: 11145307]
- Lucerna, S.; Salpietro, FM.; Alafaci, C.; Tomasello, F. *In vivo atlas of deep brain structures*. Springer; New York: 2004.
- Mai, JK.; Assheuer, J.; Paxinos, G. *Atlas of the human brain*. 2nd.. Elsevier Academic Press; Amsterdam: 2004.
- Mega MS, Dinov ID, Mazziotta JC, Manese M, Thompson PM, et al. Automated brain tissue assessment in the elderly and demented population: Construction and validation of a sub-volume probabilistic brain atlas. *Neuroimage* 2005;26:1009–1018. [PubMed: 15908234]
- Mori, S.; Wakana, S.; Van Zijl, PCM. *Mri atlas of human white matter*. 1st.. Elsevier; Amsterdam, The Netherlands: 2004.
- Morosan P, Rademacher J, Schleicher A, Amunts K, Schormann T, et al. Human primary auditory cortex: Cytoarchitectonic subdivisions and mapping into a spatial reference system. *NeuroImage* 2001;13:684–701. [PubMed: 11305897]
- Nielsen FA, Hansen LK. Modeling of activation data in the brainmap database: Detection of outliers. *Hum Brain Mapp* 2002;15:146–156. [PubMed: 11835605]
- Ono, M.; Kubik, S.; Abernathy, CD. *Atlas of the cerebral sulci*. Thieme Medical Publishers, Inc.; New York: 1990.
- Passingham RE, Stephan KE, Kotter R. The anatomical basis of functional localization in the cortex. *Nat Rev Neurosci* 2002;3:606–616. [PubMed: 12154362]
- Penhune VB, Zatorre RJ, Macdonald JD, Evans AC. Interhemispheric anatomical differences in human primary auditory cortex: Probabilistic mapping and volume measurement from magnetic resonance scans. *Cerebral Cortex* 1996;6:661–672. [PubMed: 8921202]
- Petrides M. Lateral prefrontal cortex: Architectonic and functional organization. *Philos Trans R Soc Lond B Biol Sci* 2005;360:781–795. [PubMed: 15937012]
- Poldrack RA. Can cognitive processes be inferred from neuroimaging data? *Trends Cogn Sci* 2006;10:59–63. [PubMed: 16406760]
- Rademacher J, Morosan P, Schormann T, Schleicher A, Werner C, et al. Probabilistic mapping and volume measurement of human primary auditor cortex. *NeuroImage* 2001;13:669–683. [PubMed: 11305896]
- Rajkowska G, Goldman-Rakic PS. Cytoarchitectonic definition of prefrontal areas in the normal human cortex: Ii. Variability in locations of areas 9 and 46 and relationship to the talairach coordinate system. *Cereb Cortex* 1995;5:323–337. [PubMed: 7580125]
- Saxe R, Brett M, Kanwisher N. Divide and conquer: A defense of functional localizers. *Neuroimage* 2006;30:1088–1096. 1097–1089. [PubMed: 16635578]
- Schmahmann, JD.; Doyon, J.; Toga, AW.; Petrides, M.; Evans, A. *Mri atlas of the human cerebellum*. Academic Press; London: 2000.
- Sereno MI, Dale AM, Reppas JB, Kwong KK, Belliveau JW, et al. Borders of multiple visual areas in humans revealed by functional magnetic resonance imaging. *Science* 1995;268:889–893. [PubMed: 7754376]
- Talairach, J.; Tournoux, P. *Co-planar stereotaxic atlas of the human brain*. Thieme; Stuttgart: 1988.
- Thompson PM, Cannon TD, Narr KL, van Erp T, Poutanen VP, et al. Genetic influences on brain structure. *Nat Neurosci* 2001;4:1253–1258. [PubMed: 11694885]
- Thompson PM, Schwartz C, Lin RT, Khan AA, Toga AW. Three-dimensional statistical analysis of sulcal variability in the human brain. *J Neurosci* 1996;16:4261–4274. [PubMed: 8753887]

- Tootell RB, Mendola JD, Hadjikhani NK, Ledden PJ, Liu AK, et al. Functional analysis of v3a and related areas in human visual cortex. *J Neurosci* 1997;17:7060–7078. [PubMed: 9278542]
- Tzourio-Mazoyer N, Landeau B, Papathanassiou D, Crivello F, Etard O, et al. Automated anatomical labeling of activations in spm using a macroscopic anatomical parcellation of the mni mri single-subject brain. *Neuroimage* 2002;15:273–289. [PubMed: 11771995]
- Uylings HB, Rajkowska G, Sanz-Arigita E, Amunts K, Zilles K. Consequences of large interindividual variability for human brain atlases: Converging macroscopical imaging and microscopical neuroanatomy. *Anat Embryol (Berl)* 2005;210:423–431. [PubMed: 16180019]
- Van Essen DC. A population-average, landmark- and surface-based (pals) atlas of human cerebral cortex. *Neuroimage* 2005;28:635–662. [PubMed: 16172003]
- Vanduffel W, Fize D, Peuskens H, Denys K, Sunaert S, et al. Extracting 3d from motion: Differences in human and monkey intraparietal cortex. *Science* 2002;298:413–415. [PubMed: 12376701]
- Woolsey, TA.; Hanaway, J.; Gado, MH. The brain atlas: A visual guide to the human central nervous system. Wiley; Hoboken, N.J: 2003.
- Zilles K, Armstrong E, Schleicher A, Kretschmann HJ. The human pattern of gyrification in the cerebral cortex. *Anat Embryol (Berl)* 1988;179:173–179. [PubMed: 3232854]
- Zilles K, Schlaug G, Matelli M, Luppino G, Schleicher A, et al. Mapping of human and macaque sensorimotor areas by integrating architectonic, transmitter receptor, mri and pet data. *J Anat* 1995;187 (Pt 3):515–537. [PubMed: 8586553]

Appendix: Web sites for anatomical localization

Site name	URL	Purpose
Neuroimaging Validation Dataset Wiki	http://www.fmridc.org/wiki/	Portal for online neuroimaging data
UCLA Laboratory of NeuroImaging	http://www.loni.ucla.edu/Atlases/	ICBM and other atlases available for download
Whole Brain Atlas	http://www.med.harvard.edu/AANLIB/home.html	Interactive brain atlases
SumsDB	http://sumsdb.wustl.edu/	Interactive brain atlases
Digital Anatomist Interactive Atlases	http://www9.biostr.washington.edu/da.html	Interactive brain atlases
BrainInfo	http://braininfo.rprc.washington.edu/	NeuroNames Browser, Interactive brain atlases
Guidelines for presenting neuroimaging analyses	http://www.sph.umich.edu/~nichols/NIPub/	Best practices for presentation of fMRI methods

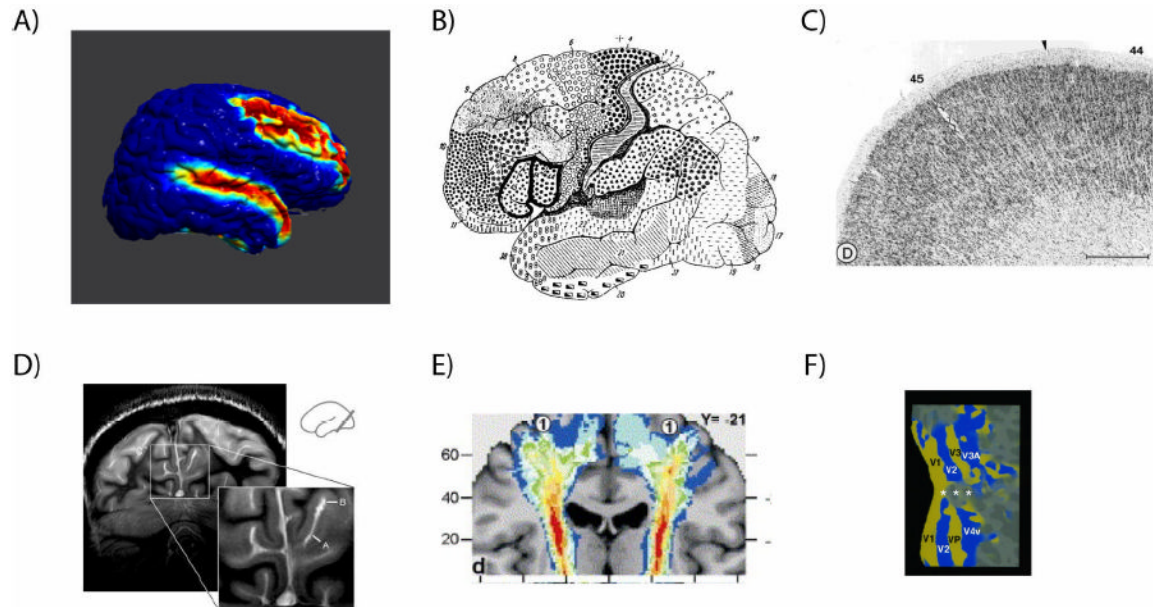


Figure 1.

Examples of various levels of neuroanatomy. A). Gyral macroanatomy: Probability map of location of middle frontal gyrus and superior temporal gyrus (Shattuck, Hojatkashani, Mirza, Adisetiyo, Salamon, *et al.*, 2006). B). Microanatomy: Brodmann's (Brodmann, 1909) original map of cytoarchitecturally-distinguished cortical regions, with areas 44 and 45 outlined (Amunts, Schleicher, Burgel, Mohlberg, Uylings, *et al.*, 1999). C). Microanatomy: Microscopic image of cytoarchitecture of Brodmann's areas 44 and 45 (Amunts, Schleicher, Burgel, Mohlberg, Uylings, *et al.*, 1999); these areas are distinguished by the lack of a clearly visible layer IV, with the arrow noting the point of transition between regions. D) Myeloarchitecture: High-resolution MRI imaging showing the stria of Gennari in the occipital cortex (Clare and Bridge, 2005). E) Connectional architecture: Probability map of the location of the corticospinal tract in 10 individuals, identified from myelin-stained postmortem histological sections (Burgel, Amunts, Hoemke, Mohlberg, Gilsbach, *et al.*, 2006). F) Functional anatomy: Retinotopic visual areas identified using fMRI (Tootell, Mendola, Hadjikhani, Ledden, Liu, *et al.*, 1997).

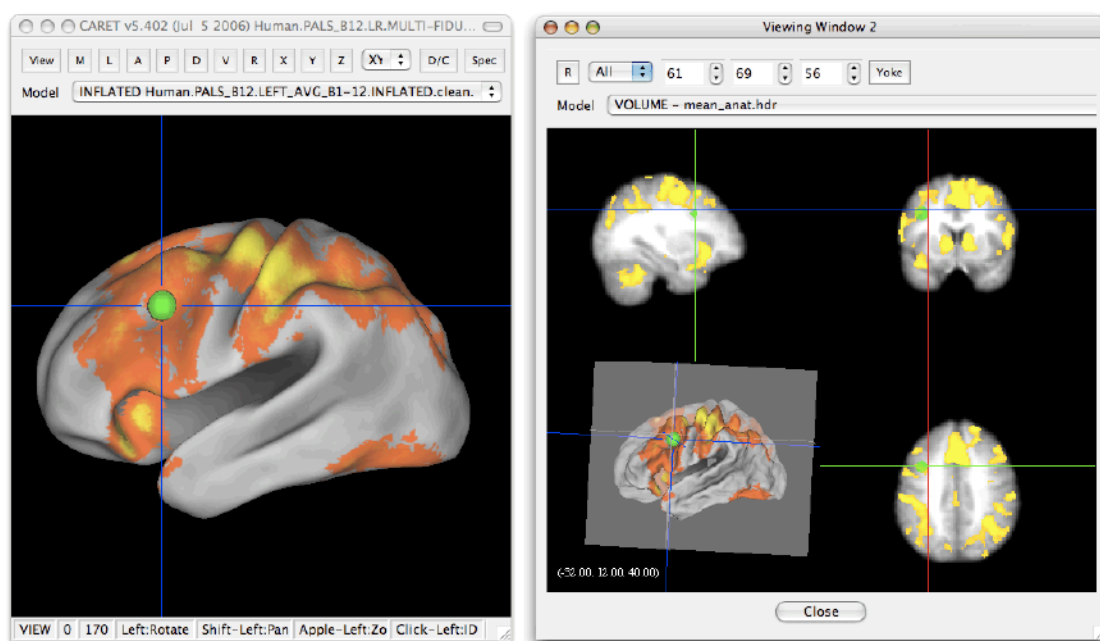


Figure 2. Example of simultaneous visualization of group functional activation on population cortical surface (left panel) and averaged anatomy (right panel) using CARET software (Van Essen, 2005). The group statistical map was mapped to the population cortical surface using multifiducial mapping.